



PATIENT PRESENTING CLINICAL SIGNS

Fiona Sheehy Pt had first heat at end of Nov/beginning of Dec. O has intact male in the house, and they latched on Dec 9th.

SPECIES RADIOGRAPHIC STUDY OF THE ABDOMEN

Canine Right /left lateral and ventrodorsal views of the abdomen totaling 4 images available for review.

RADIOGRAPHIC FINDINGS

BREED

French Bulldog

The uterus is prominently enlarged measuring ~ 4.5 cm. The uterine horns are measuring ~ 4.5 cm in diameter with mild segmentation noted along its length. The enlargement is uniformly soft tissue opaque.

SEX

No fetal skeletal mineralization is identifiable within the uterine lumen.

FI

The abdominal serosal detail is maintained; no other abdominal abnormalities are apparent.

RADIOGRAPHIC DIAGNOSIS

AGE

10mo

- Uterine enlargement consistent with one of the following, early pregnancy prior to radiographically detectable fetal mineralization or hydrometra such as pyometra, endometrial changes or cystic endometrial disease which is uncommon in a 10 month old patient without clinical signs

INTERPRETED BY

Nele Eley (Ondreka),
DVM Dr. med. vet.,
DipECVDI

INTERPRETATION OF FINDINGS & FURTHER RECOMMENDATIONS

Radiographically fetal skeletal mineralization in dogs typically becomes apparent between 42 and 45 days post ovulation, ~ 6 weeks. Given the reported mating date of end of November/early December, the dog would be on the edge of 5-6 weeks post mating at the time of imaging, which is borderline for detecting skeletal mineralization, but often skeletal structures are not yet visible. Therefore, an intact pregnancy remains possible, but definitive confirmation by ultrasound is recommended which can detect embryonic vesicles as early as 21 - 25 days post ovulation.

HOSPITAL NAME

The Pet Hospital of
Stratford

REFERRING VET

Dr Guiliani

INVOICE

23559

DATE

01/14/2026



PATIENT

Fiona Sheehy

SPECIES

Canine

BREED

French Bulldog

SEX

FI

AGE

10mo

INTERPRETED BY

Nele Eley (Ondreka),
DVM Dr. med. vet.,
DipECVDI

HOSPITAL NAME

The Pet Hospital of
Stratford

REFERRING VET

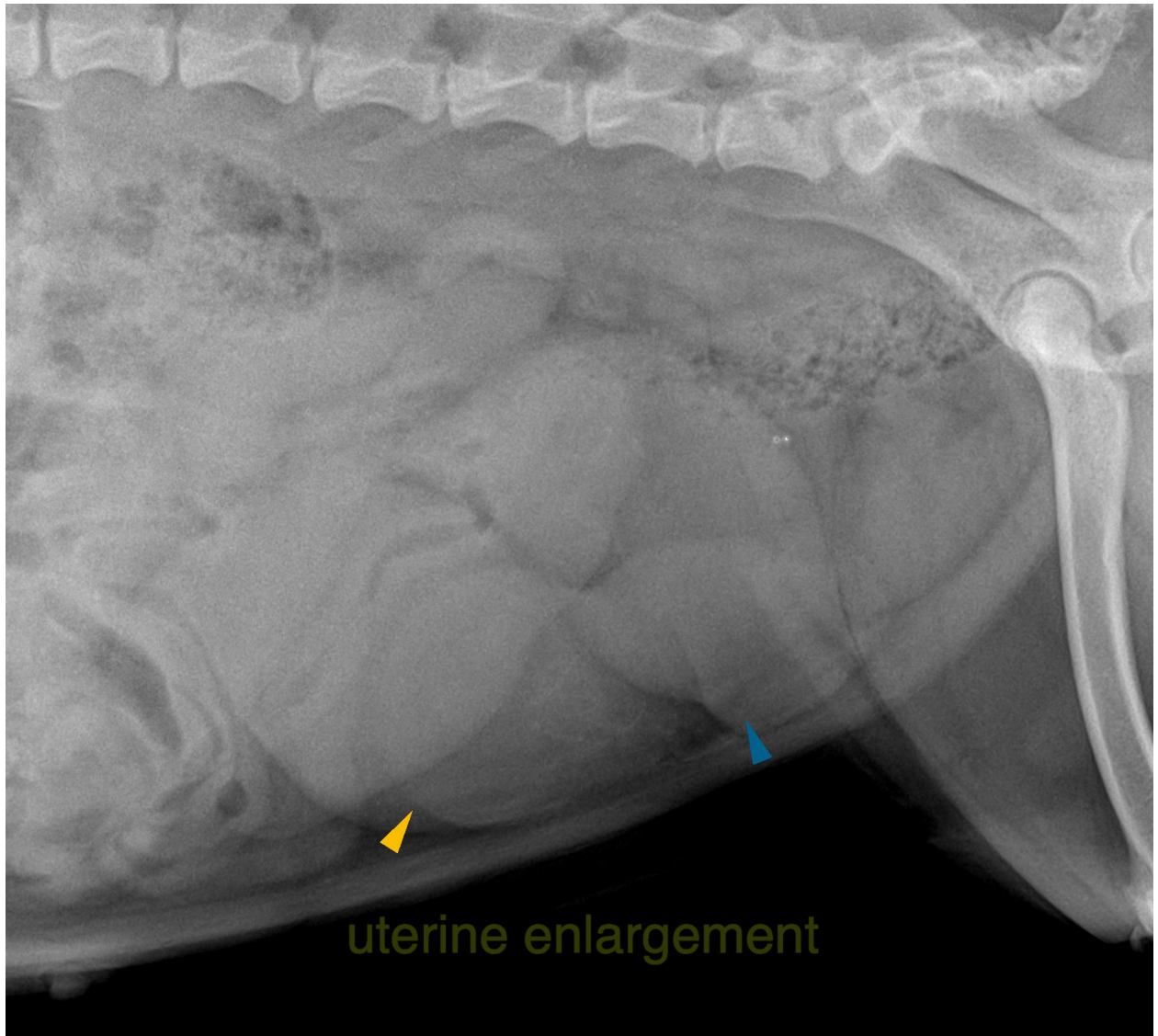
Dr Guiliani

INVOICE

23559

DATE

01/14/2026





PATIENT

Fiona Sheehy

The information and recommendations provided are based on the images presented by the referring veterinarian. No evaluation can be communicated regarding pathology that was not visible in the image/video clips provided.

SPECIES

Canine

Thank you for this referral. If the clinical or image interpretation does not parallel your findings or if I can be of any further assistance please contact me.

BREED

French Bulldog

Nele Eley (Ondreka), DVM, Dr. med. vet., DipECVDI
European Specialist in Veterinary Diagnostic Imaging, Cert. Radiology,
Senior lecturer University of Giessen/Germany, Veterinary Faculty, Department of Radiology.
info@sonopath.com

SEX

FI

AGE

10mo

INTERPRETED BY

Nele Eley (Ondreka),
DVM Dr. med. vet.,
DipECVDI

HOSPITAL NAME

The Pet Hospital of
Stratford

REFERRING VET

Dr Guiliani

INVOICE

23559

DATE

01/14/2026